

Haruhito Adam Uchida^{1,2*}, Hatsuzo Uchida³ and Jun Wada²

¹Department of Chronic Kidney Disease and Cardiovascular Disease, Okayama University Graduate School of Medicine, Dentistry and Pharmaceutical Sciences, Okayama, Japan

²Department of Medicine and Clinical Science, Okayama University Graduate School of Medicine, Dentistry and Pharmaceutical Sciences, Okayama, Japan

³Department of Angiology, Bitchu Kokubunji Clinic, Kurashiki, Japan

Dates: Received: October 20, 2014; Accepted: October 24, 2014; Published: October 27, 2014

*Corresponding author: Haruhito A. Uchida, M.D, PhD, Department of Chronic Kidney Disease and Cardiovascular Disease, Okayama University Graduate School of Medicine, Dentistry and Pharmaceutical Sciences, 2-5-1 Shikata-cho Kita-ku, Okayama, 700-8558, Japan, Tel: (+81) 86-235-7235; Fax: (+81) 86-222-5214; E-mail: hauchida@md.okayama-u.ac.jp

www.peertechz.com

Keywords: Endothelial function; Smoking; Aliskiren; Interleukin-6

ISSN: 2455-2976

Short Communication

Acute Effect of Aliskiren on Smoking-Induced Endothelial Dysfunction in Smoker

Abstract

Background: We aimed to examine the acute effect of aliskiren on smoking-induced endothelial dysfunction in smoker.

Methods: Nineteen male smokers were enrolled. After all participants smoked a cigarette, their endothelial function was assessed with brachial artery flow mediated dilation (FMD). An hour after the administration of aliskiren, they smoked again, their FMD was assessed again. A month later, all measurements were performed again without the administration of aliskiren as a control. Blood pressure, plasma renin activity, and serum interleukin-6 concentration were also examined at the same time of FMD measurement.

Results: A cigarette smoking led to an acute endothelial dysfunction ($6.5 \pm 1.7\%$ to $3.4 \pm 1.0\%$, $P = 0.02$). Aliskiren administration significantly suppressed blood pressure and plasma renin activity, furthermore, improved FMD ($6.7 \pm 0.5\%$ to $8.1 \pm 0.8\%$, $P = 0.03$). Aliskiren significantly reduced serum interleukin-6 concentration, but not in control.

Conclusion: Aliskiren has a beneficial effect on smoking-induced acute endothelial dysfunction.

Abbreviation

RAS: Renin-angiotensin System, ACE-I: Angiotensin Converting Enzyme Inhibitor, ARB: Angiotensin II Receptor Blocker, BP: Blood Pressure, FMD: Flow Mediated Dilatation.

Introduction

Smoking is one of the major cardiovascular risk factors, as well as hypertension, diabetes mellitus, and dyslipidemia. Increasing evidence strongly suggests that smoking is associated with impaired endothelial function and increased inflammatory status [1-3]. Endothelial dysfunction is known as an initial step in the progression of atherosclerosis. Thus, clinical strategy to preserve or improve endothelial function has been required to prevent consequent cardiovascular events [4].

Aliskiren is the first agent to inhibit renin activity, the upper stream of renin-angiotensin system (RAS). Similar to other RAS inhibitors, such as angiotensin converting enzyme inhibitor (ACE-I) or angiotensin II receptor blocker (ARB), several studies have reported clinical efficacy of aliskiren not only on blood pressure (BP) reduction but also on organ protection [5-10]. In addition, ACE-I or ARB have been shown to have a beneficial effect on endothelial function in the patients with hypertension [11,12]. However, little is known the effect of aliskiren on endothelial function in clinical setting.

Therefore, in this study, we aimed to examine the acute effect of aliskiren on smoking-induced endothelial dysfunction.

Methods

The study enrolled nineteen male smokers aged 41 ± 2 (27 to 51) years old that had no cardiovascular risk factors other than smoking. All measurements were performed in the early morning, before breakfast, refraining from smoking more than 12 hours. At first, each participant took two puffs of a cigarette which contained 8 mg of tar and 0.7 mg of nicotine. Immediately, endothelial function was assessed with brachial artery flow mediated dilation (FMD) using UNEXEF18G (UNEX Co.Nagoya, Japan) [13]. Then, all participants took a 150 mg of aliskiren. An hour later, following another two puffs of cigarette taken, FMD were evaluated again. Plasma renin activity, serum interleukin-6 (IL-6), thrombomodulin (TM) and asymmetric dimethylarginine (ADMA) concentration were examined before and an hour later. BP was also measured at supine position just before FMD measurement. A month later, all measurements were performed again without the administration of aliskiren as a control. This study was approved by Okayama University Institutional Review Board (accredited ISO9001/2000). All participants gave written consents. Data were presented as means \pm SEM. Changes in parameters were evaluated by paired t test. Results with $P < 0.05$ were deemed statistically significant.

Results

Aliskiren administration significantly reduced both systolic and diastolic BP ($P < 0.01$, each) without any change in pulse rate (Table 1). Plasma renin activity dramatically decreased in all

Table 1: Changes in parameters between before and an hour after treatment with/without Aliskiren.

Parameter	Aliskiren			Control		
	before	after	P value	before	after	P value
Systolic Blood Pressure	128 ± 2	117 ± 3	0.0071	122 ± 2	121 ± 3	0.7727
Diastolic Blood Pressure	79 ± 3	69 ± 2	<0.0001	76 ± 3	74 ± 2	0.3052
Pulse Rate	69 ± 2	71 ± 2	0.1101	57 ± 2	60 ± 2	0.1987
Plasma Renin Activity	1.57 ± 0.19	0.35 ± 0.07	<0.0001	0.92 ± 0.19	1.00 ± 0.07	0.4186
Interleukin - 6	1.03 ± 0.11	0.96 ± 0.09	0.0442	0.80 ± 0.11	0.73 ± 0.09	0.3276
Thrombomodulin	2.47 ± 0.10	2.53 ± 0.11	0.3874	2.67 ± 0.10	2.70 ± 0.11	0.7497
Asymmetric Dimethylarginine	0.445 ± 0.011	0.439 ± 0.012	0.3540	0.422 ± 0.011	0.395 ± 0.012	0.0673

Data were presented as means ± SEM. P value was determined by paired t test.

patients ($P < 0.0001$, Table 1). Meanwhile, no significant changes of BP were seen in control.

In control, a cigarette smoking impaired FMD (from $6.5 \pm 1.7\%$ to $3.4 \pm 1.0\%$, $P = 0.0204$, Figure 1). However, aliskiren treatment significantly improved FMD (from $6.7 \pm 0.5\%$ to $8.1 \pm 0.8\%$, $P = 0.0321$, Figure 1).

Aliskiren reduced serum IL-6 concentration ($P = 0.0442$, Table 1) but not in control. No significant change in serum TM and ADMA concentration was found (Table 1).

We also performed stratified analysis between high FMD group (baseline FMD $\geq 6.0\%$, $n=9$) and low FMD group (baseline FMD $< 6.0\%$, $n=10$). In each group, aliskiren reduced both systolic and diastolic BP (high FMD group: from $125 \pm 3/77 \pm 2$ mmHg to $115 \pm 3/68 \pm 3$ mmHg, $P = 0.0026$ (systolic BP) and 0.0148 (diastolic BP), low FMD group: from $130 \pm 4/81 \pm 2$ mmHg to $119 \pm 5/70 \pm 2$ mmHg, $P < 0.0001$ each BP). Aliskiren increased FMD in high FMD group (from $8.0 \pm 0.5\%$ to $9.0 \pm 1.0\%$, Figure 2) and tended to improve FMD in low FMD group (from $4.9 \pm 0.2\%$ to $6.6 \pm 0.9\%$, $P = 0.0666$, Figure 2), although these changes were not statistically significant. Of note, 6 of 10 in low FMD group achieved their FMD levels of more than 6.0% .

Discussion

In this study, we found for the first time that aliskiren improved smoking-induced acute endothelial dysfunction and vascular inflammation in smoker. Thus, aliskiren may have a beneficial effect on vascular function.

Smoking impairs endothelial function. Endothelial dysfunction progresses atherosclerosis, leading to cardiovascular events. Therefore, several clinical strategies to ameliorate endothelial dysfunction have been investigated. Importantly, cigarette heaviness, whether regular or light, has no significant effect on smoking-induced endothelial dysfunction [14,15], although regular cigarette was used in our study. Smoking cessation is the best method to restore smoking-induced endothelial dysfunction [16]. Unfortunately, many smokers are still unable to refrain from smoking in clinical setting in spite of many items for smoking cessation or physician's strong recommendation. Thus, the alternative method is required other than smoking cessation. It has been reported several agents also improve

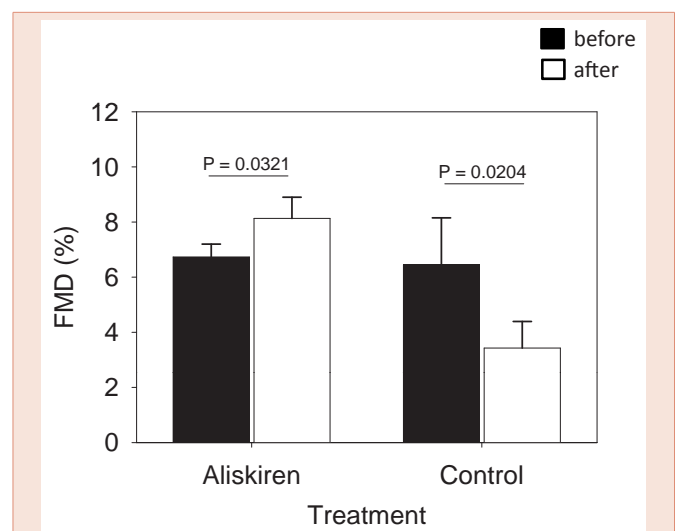


Figure 1: Changes in flow mediated dilation. Black bar represents before treatment. White bar represents 1 hour after treatment with/without aliskiren. Error bar means SEM. Each P value was determined by paired t test in comparison between before and after.

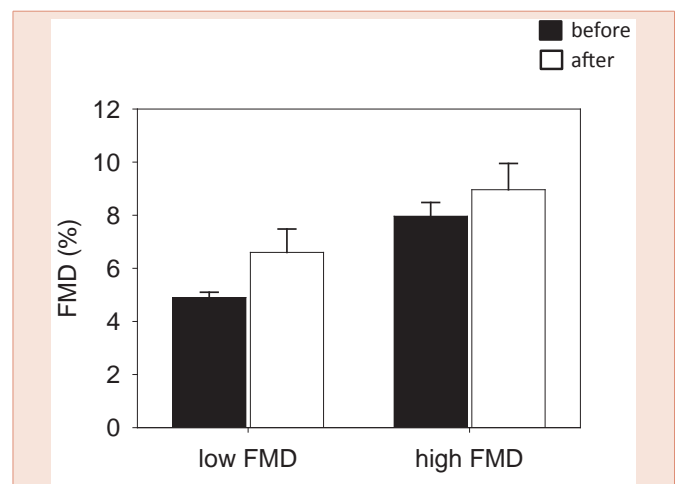


Figure 2: Stratified analysis in flow mediated dilation in low FMD group and high FMD group. Black bar represents before treatment. White bar represents 1 hour after treatment with/without aliskiren. Error bar means SEM. Each P value was determined by paired t test in comparison between before and after.

endothelial dysfunction in chronic smoker [17-19]. In the current study, aliskiren was found to ameliorate acute effect of smoking-induced endothelial dysfunction.

Since plasma renin activity in all participants decreased an hour after drug administration, we confirmed that time of onset of aliskiren was very fast, as described previously [20]. The reduction of BPs supported this rapid action. Regarding endothelial function, several studies have reported that ACE-I and ARB improve FMD in hypertensive patients, however, these properties increase plasma renin activity. On the other hand, aliskiren improved FMD but decreased plasma renin activity in the present study. Thus, the improvement of endothelial dysfunction is not associated with plasma renin activity. In addition, stratified analysis implied that aliskiren exerted beneficial effect on FMD irrespective of baseline FMD level. Taken together, aliskiren may be a new option in the treatment of patients with endothelial dysfunction.

This study was not designed to examine the molecular mechanisms underlying the effect of aliskiren on endothelial function, but the result from this study raised several possible mechanisms. One possible mechanism of an improvement of impaired-endothelial function might be provided by anti-oxidant properties of aliskiren, as seen in statin, Vitamin C and E, or other anti-oxidant agent [21-24]. Indeed, in animal study, it has been reported that aliskiren protects against atherosclerosis, through increase of eNOS production and decrease of oxidative stress [25-27]. Nevertheless, TM and ADMA did not improve in this study. This might be because time course to investigate an acute effect of the drug in the current study was too short for TM and ADMA to be changed. The other possible mechanism might be due to the anti-inflammatory effect of aliskiren. IL-6 receptor inhibitor improves inflammation-induced endothelial dysfunction in clinical setting [28,29] and treatment of dextromethorphan improves endothelial function accompanied with the decreases in serum IL-6 concentration in male heavy smokers [17]. Thus it is likely that anti-inflammation is associated with the improvement of FMD. In the current study, the significant decrease of IL-6 concentration after aliskiren administration demonstrates an acute effect of aliskiren on inflammation.

Among nineteen participants, 8 are daily smoker, and 11 are non-daily smoker. Of note, daily smoker and non-daily smoker had no significant difference in BP, FMD and all other plasma parameters in any time point (data not shown). This result indicates that habitual smoking itself, not numbers of cigarettes smoked per day, may be the risk of endothelial dysfunction. Moreover, aliskiren retarded smoking-induced endothelial dysfunction of both daily smoker and non-daily smoker in similar fashion (data not shown).

The present study had some limitations. First, this was an open-label study, and the number of participants enrolled in our study was small. Therefore, a degree of selection bias may have occurred. Second, this study demonstrated only acute efficacy. However, the result clearly indicates the rapid and beneficial

effect of aliskiren on vascular dysfunction and inflammation induced by smoking. Third, we enrolled only male, thus did not examine its effect on female. Fourth, most of current guidelines for hypertension recommend that casual BP should be measured at sitting position, meanwhile, all BP measurement in this study were conducted at supine position. Unfortunately, we did not measure casual BP at sitting position.

Conclusion

Aliskiren has a beneficial effect on smoking-induced endothelial dysfunction. Further study is needed to investigate the influence of long time treatment of aliskiren on endothelial dysfunction, moreover, cardiovascular events in a large study population with not only smoking but also other disease.

Acknowledgements

We thank Ruriko Tanaka for technical support to measure FMD.

Conflict of interest

Haruhito A. Uchida belongs to the endowed department by Chugai pharmaceutical, MSD, Boehringer Ingelheim and Kawanishi Holdings. Jun Wada is a consultant for Astellas, Boehringer Ingelheim, and receives speaker honoraria from Novartis, Boehringer Ingelheim, Novo Nordisk.

References

1. Santo-Tomas M, Lopez-Jimenez F, Machado H, Aldrich HR, Lamas GA, et al. (2002) Effect of cigar smoking on endothelium-dependent brachial artery dilation in healthy young adults. *Am Heart J* 143: 83-86.
2. Esen AM, Barutcu I, Acar M, Degirmenci B, Kaya D, et al. (2004) Effect of smoking on endothelial function and wall thickness of brachial artery. *Circ J* 68: 1123-1126.
3. Karatzi K, Papamichael C, Karatzis E, Papaioannou TG, Stamatelopoulos K, et al. (2007) Acute smoke-induced endothelial dysfunction is more prolonged in smokers than in non-smokers. *Int J Cardiol* 120: 404-406.
4. Yeboah J, Folsom AR, Burke GL, Johnson C, Polak JF, et al. (2009) Predictive value of brachial flow-mediated dilation for incident cardiovascular events in a population-based study: the multi-ethnic study of atherosclerosis. *Circulation* 120: 502-509.
5. Parving HH, Persson F, Lewis JB, Lewis EJ, Hollenberg NK, et al. (2008) Aliskiren combined with losartan in type 2 diabetes and nephropathy. *N Engl J Med* 358: 2433-2446.
6. Solomon SD, Appelbaum E, Manning WJ, Verma A, Berglund T, et al. (2009) Effect of the direct Renin inhibitor aliskiren, the Angiotensin receptor blocker losartan, or both on left ventricular mass in patients with hypertension and left ventricular hypertrophy. *Circulation* 119: 530-537.
7. McMurray JJ, Pitt B, Latini R, Maggioni AP, Solomon SD, et al. (2008) Effects of the oral direct renin inhibitor aliskiren in patients with symptomatic heart failure. *Circ Heart Fail* 1: 17-24.
8. Persson F, Rossing P, Reinhard H, Juhl T, Stehouwer CD, et al. (2009) Renal effects of aliskiren compared with and in combination with irbesartan in patients with type 2 diabetes, hypertension, and albuminuria. *Diabetes Care* 32: 1873-1879.
9. Ogawa S, Nako K, Okamura M, Senda M, Mori T, et al. (2011) Aliskiren reduces albuminuria and oxidative stress, and elevates glomerular filtration rates in Japanese patients with advanced diabetic nephropathy. *Hypertens Res* 34: 400-401.

10. Brown MJ, McInnes GT, Papst CC, Zhang J, MacDonald TM, et al. (2011) Aliskiren and the calcium channel blocker amlodipine combination as an initial treatment strategy for hypertension control (ACCELERATE): a randomised, parallel-group trial. *Lancet* 377: 312-320.
11. Hirooka Y, Kimura Y, Sagara Y, Ito K, Sunagawa K, et al. (2008) Effects of valsartan or amlodipine on endothelial function and oxidative stress after one year follow-up in patients with essential hypertension. *Clin Exp Hypertens* 30: 267-276.
12. Tezcan H, Yavuz D, Toprak A, Akpinar I, Koc M, et al. (2003) Effect of angiotensin-converting enzyme inhibition on endothelial function and insulin sensitivity in hypertensive patients. *J Renin Angiotensin Aldosterone Syst* 4: 119-123.
13. Tomiyama H, Yamashina A (2010) Non-invasive vascular function tests: their pathophysiological background and clinical application. *Circ J* 74: 24-33.
14. Ciftci O, Gunday M, Caliskan M, Gullu H, Guven A, et al. (2013) Light cigarette smoking and vascular function. *Acta Cardiol* 68: 255-261.
15. Amato M, Frigerio B, Castelnuovo S, Ravani A, Sansaro D, et al. (2013) Effects of smoking regular or light cigarettes on brachial artery flow-mediated dilation. *Atherosclerosis* 228: 153-160.
16. Johnson HM, Gossett LK, Piper ME, Aeschlimann SE, Korcarz CE, et al. (2010) Effects of smoking and smoking cessation on endothelial function: 1-year outcomes from a randomized clinical trial. *J Am Coll Cardiol* 55: 1988-1995.
17. Liu PY, Lin CC, Tsai WC, Li YH, Lin LJ, et al. (2008) Treatment with dextromethorphan improves endothelial function, inflammation and oxidative stress in male heavy smokers. *J Thromb Haemost* 6: 1685-1692.
18. Yoshida O, Kondo T, Kureishi-Bando Y, Sugiura T, Maeda K, et al. (2010) Pitavastatin, an HMG-CoA reductase inhibitor, ameliorates endothelial function in chronic smokers. *Circ J* 74: 195-202.
19. Kim KS, Park HS, Jung IS, Park JH, Ahn KT, et al. (2011) Endothelial dysfunction in the smokers can be improved with oral cilostazol treatment. *J Cardiovasc Ultrasound* 19: 21-25.
20. Limoges D, Dieterich HA, Yeh CM, Vaidyanathan S, Howard D, et al. (2008) A study of dose-proportionality in the pharmacokinetics of the oral direct renin inhibitor aliskiren in healthy subjects. *Int J Clin Pharmacol Ther* 46: 252-258.
21. Yamaguchi Y, Matsuno S, Kagota S, Haginaka J, Kunitomo M, et al. (2004) Peroxynitrite-mediated oxidative modification of low-density lipoprotein by aqueous extracts of cigarette smoke and the preventive effect of fluvastatin. *Atherosclerosis* 172: 259-265.
22. Plantinga Y, Ghiadoni L, Magagna A, Giannarelli C, Franzoni F, et al. (2007) Supplementation with vitamins C and E improves arterial stiffness and endothelial function in essential hypertensive patients. *Am J Hypertens* 20: 392-397.
23. Siasos G, Tousoulis D, Vlachopoulos C, Antoniadou C, Stefanadi E, et al. (2009) The impact of oral L-arginine supplementation on acute smoking-induced endothelial injury and arterial performance. *Am J Hypertens* 22: 586-592.
24. Koh KK, Quon MJ, Han SH, Lee Y, Ahn JY, et al. (2008) Simvastatin improves flow-mediated dilation but reduces adiponectin levels and insulin sensitivity in hypercholesterolemic patients. *Diabetes Care* 31: 776-782.
25. Dong YF, Liu L, Kataoka K, Nakamura T, Fukuda M, et al. (2010) Aliskiren prevents cardiovascular complications and pancreatic injury in a mouse model of obesity and type 2 diabetes. *Diabetologia* 53: 180-191.
26. Imanishi T, Tsujioka H, Ikejima H, Kuroi A, Takarada S, et al. (2008) Renin inhibitor aliskiren improves impaired nitric oxide bioavailability and protects against atherosclerotic changes. *Hypertension* 52: 563-572.
27. Habibi J, Whaley-Connell A, Hayden MR, DeMarco VG, Schneider R, et al. (2008) Renin inhibition attenuates insulin resistance, oxidative stress, and pancreatic remodeling in the transgenic Ren2 rat. *Endocrinology* 149: 5643-5653.
28. Protogerou AD, Zampeli E, Fragiadaki K, Stamatelopoulos K, Papamichael C, et al. (2011) A pilot study of endothelial dysfunction and aortic stiffness after interleukin-6 receptor inhibition in rheumatoid arthritis. *Atherosclerosis* 219: 734-736.
29. Antoniadou C, Demosthenous M, Tousoulis D, Antonopoulos AS, Vlachopoulos C, et al. (2011) Role of asymmetrical dimethylarginine in inflammation-induced endothelial dysfunction in human atherosclerosis. *Hypertension* 58: 93-98.

Copyright: © 2014 Uchida HA, et al. This is an open-access article distributed under the terms of the Creative Commons Attribution License, which permits unrestricted use, distribution, and reproduction in any medium, provided the original author and source are credited.

Citation: Uchida HA, Uchida H, Wada J (2014) Acute Effect of Aliskiren on Smoking-Induced Endothelial Dysfunction in Smoker. *J Cardiovasc Med Cardiol* 1(2): 038-041. DOI: 10.17352/2455-2976.000010