

Maia Eng[#], William Wung[#], Uma N Srivatsa[#] and Gagan D Singh^{*#}

¹Division of Cardiovascular Medicine, University of California (Davis) Medical Center, Sacramento, CA, USA

[#]Contributed equally

Dates: Received: 09 June, 2017; **Accepted:** 29 June, 2017; **Published:** 30 June, 2017

***Corresponding author:** Gagan D Singh, Assistant Professor, Division of Cardiovascular Medicine, University of California Davis Medical Center, 4860 Y Street, Suite 2820, Sacramento CA 95817, USA, E-mail: drsingh@ucdavis.edu

<https://www.peertechz.com>

Case Report

“C” Trouble: Class IC Anti-arrhythmic Toxicity

Introduction

The most common cardiac arrhythmia encountered in clinical practice is atrial fibrillation (AFib). AFib has significant effects on long-term mortality and stroke, and contributes greatly to overall healthcare costs, affects quality of life and the functional status of many patients [1]. The incidence and prevalence of AFib continues to rise with age, when comorbidities that affect rhythm management frequently co-exist [1].

Due to improved quality of life, rhythm control is a common treatment strategy [2,3]. This is accomplished with the use of antiarrhythmic agents across the Singh-Vaughn-Williams classification [4]. In patients with structurally normal hearts, Class IC agents such as flecainide and propafenone are commonly prescribed for maintenance of sinus rhythm as the first line therapy [5]. Despite their prevalent use, the relative toxicities of these agents are infrequent, and therefore seldom emphasized in the most recent guidelines and reviews [4]. The lack of survival benefit from rhythm management strategy utilizing antiarrhythmic drugs have been suggested to be due to adverse effects from these agents [6]. The mechanism of action is on the cellular action potential and can be pro-arrhythmic due to the lack of specificity on the atrial tissue. It is critical that clinicians be able to recognize the causes, signs and symptoms of toxicity from these antiarrhythmic agents.

We present two cases of drug toxicities in different clinical settings, the pathophysiology, and the overall management approach.

Case 1

A 75-year-old female with a history of paroxysmal AFib, heart failure with preserved ejection fraction, idiopathic

pulmonary fibrosis, and hypertension is admitted with fevers, chills, productive cough, worsening dyspnea, anorexia, lightheadedness, nausea and vomiting.

Approximately one year prior, the patient had recurrent bouts of debilitating palpitations. A 24-hour continuous Holter monitor confirmed the diagnosis of paroxysmal AFib. A transthoracic echocardiogram showed a structurally normal heart, and a pharmacologic stress test did not demonstrate reversible ischemia. Shortly thereafter the patient was started on flecainide 50mg orally twice a day and metoprolol succinate 25mg orally once a day; this intervention lessened the frequency of her symptoms. One month later, her flecainide was titrated up to 100mg orally twice a day resulting in complete abatement of her palpitations with follow-up electrocardiograms demonstrating stable QRS intervals (Figure 1).

On this admission, the patient's vitals were notable for an elevated temperature of 39 degrees Celsius, blood pressure of 145/56 mm Hg, heart rate of 98 beats per minute and a peripheral oxygen saturation of 98% on supplemental oxygen (60% FiO₂). She was in mild respiratory distress, tachypneic, and diaphoretic. Her respiratory exam was notable for inspiratory rales and expiratory rhonchi bilaterally. The remainder of her physical exam was unremarkable. Laboratory data was notable for a leukocytosis of 18.4 L/mm³ (ref 4.5-11 K/mm³) with left shift and bandemia (95% neutrophils, and 20% bands), serum potassium of 4.9 mEq/L (ref 3.5-5.0 mEq/L) and serum creatinine of 3.4 mg/dL (ref 0.4-1.3 mg/dL). A chest

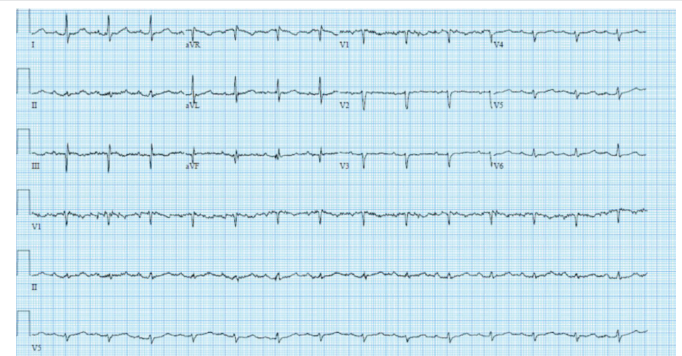

Figure 1: Baseline electrocardiogram in patient after starting flecainide demonstrating normal QRS interval.

x-ray noted a dense consolidation in the right lower lobe of the lungs and diffuse mild-moderate vascular congestion. The patient's clinical symptoms, physical examination, laboratory data, and imaging were consistent with community-acquired pneumonia with moderate acute renal insufficiency and mild decompensated diastolic heart failure. The patient was started on antibiotic therapy with ceftriaxone and azithromycin.

Electrocardiograms obtained during this admission showed a significant prolongation in her QRS and QTc intervals (Figure 2) and also non-sustained runs of wide-complex tachycardia concerning for ventricular tachyarrhythmias (Figure 3). Flecainide toxicity precipitated by acute renal insufficiency in the setting of an acute pneumonia was suspected. Flecainide was promptly discontinued but this measure alone was insufficient in improving her clinical picture. Therefore the patient was also administered 2 ampules (50 mEq each) of sodium bicarbonate over the course of 5 minutes. Shortly thereafter, the degree of ventricular ectopy subsided and her rhythm stabilized. We suspected a mild degree of decompensated heart failure with preserved ejection fraction in the setting of acute pneumonia and thus we elected not to place the patient on a sodium bicarbonate or hypertonic saline infusion. Rather, the patient was closely monitored in our intensive care unit and received 4 additional ampules of sodium bicarbonate by the following morning for increased ventricular ectopy. Within 24 hours, the patient began showing signs of clinical improvement. She was not requiring any further bicarbonate therapy, and both her renal function and electrocardiographic intervals improved

(Figure 4). She completed treatment for her community-acquired pneumonia and eventually had resolution of her renal failure. Given her propensity for renal insufficiency and pre-existing parenchymal lung disease, a rhythm control strategy for this patient was abandoned and rate control alone was sought.

Case 2

A 73-year-old male noted sudden onset of palpitations and dizziness. One year prior, similar symptoms led to the diagnosis of paroxysmal atrial flutter. Maintenance of sinus rhythm was achieved with propafenone 150mg orally three times daily. His baseline electrocardiogram (Figure 5), was notable for sinus rhythm with first-degree atrioventricular, right bundle branch block, and left anterior fascicular block. The current onset of palpitations and dizziness raised concerns for recurrent atrial flutter. The patient self-administered a loading dose of propafenone (600mg) to restore sinus rhythm. Shortly thereafter, he developed worsening nausea and dizziness, prompting him to seek evaluation in the emergency department.

On initial assessment, the patient complained of severe nausea and dizziness but denied chest pain or palpitations. Vital signs were notable for elevated blood pressure of 147/106 mm Hg and a heart rate of 102 beats per minute. The patient appeared unwell and was mildly diaphoretic. The remainder of his physical exam was unrevealing. Laboratory data included a normal complete blood count, serum potassium level of 4.8

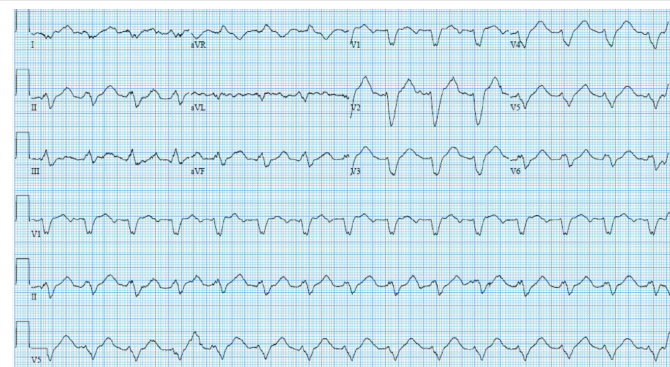


Figure 2: Electrocardiogram obtained at admission for community-acquired pneumonia showed an alarming prolongation in patient's QRS and QTc intervals.

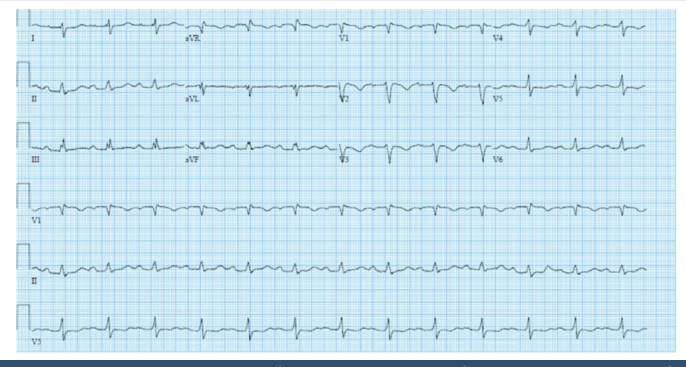


Figure 4: Electrocardiogram after administration of sodium bicarbonate for ventricular ectopy showing improvement in QRS and QTc intervals.

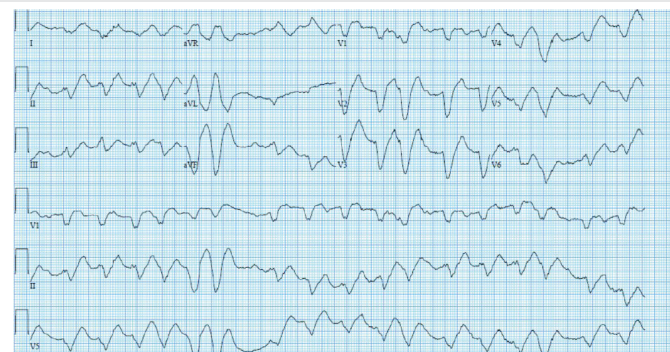


Figure 3: Non-sustained runs of wide-complex tachycardia concerning for ventricular tachyarrhythmias seen in a patient admitted for community-acquired pneumonia.

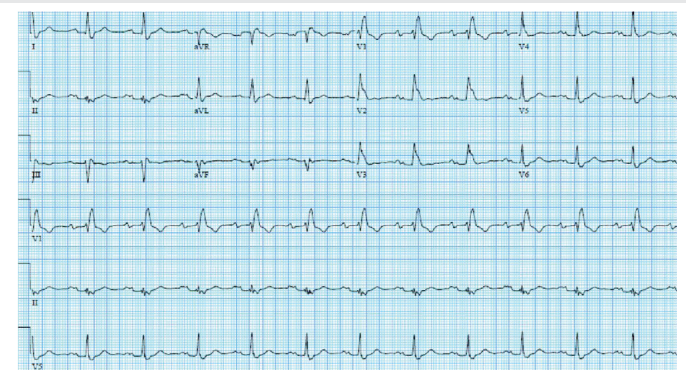


Figure 5: Baseline electrocardiogram in patient on propafenone that is notable for sinus rhythm with first-degree atrioventricular, right bundle branch, and left anterior fascicular block.

mEq/L (3.3–5.0 mEq/L), serum magnesium level of 2.2 mg/dL (1.5–2.6 mg/dL), and mildly elevated serum blood urea nitrogen of 27 mg/dL (8–22 mg/dL) and serum creatinine of 1.4 mg/dL (0.44–1.27 mg/dL). His hepatic transaminases, bilirubin, and alkaline phosphatase were within normal limits. The admission electrocardiogram (Figure 6), was notable for a regular, wide complex tachycardia with right bundle branch and left anterior fascicular block.

Given the temporal relation with medication ingestion and the onset of gastrointestinal symptoms and electrocardiographic findings, propafenone toxicity was suspected and thus discontinued accordingly. Given the patient's persistent symptoms and electrocardiographic changes, 1 ampule (50 mEq) of sodium bicarbonate was administered. An electrocardiogram obtained within 5 minutes afterwards demonstrated a dramatic narrowing of the QRS complex and emergence of atrial flutter with variable block as the underlying rhythm (Figure 7). Patient was maintained on a sodium bicarbonate continuous intravenous infusion overnight. The following morning the symptoms of nausea and dizziness had completely abated and the sodium bicarbonate infusion was discontinued; QRS duration remained at his baseline with an underlying rhythm of atrial flutter. The patient was ultimately transitioned to amiodarone prior to discharge, with plans for outpatient cardioversion and restoration of normal sinus rhythm.

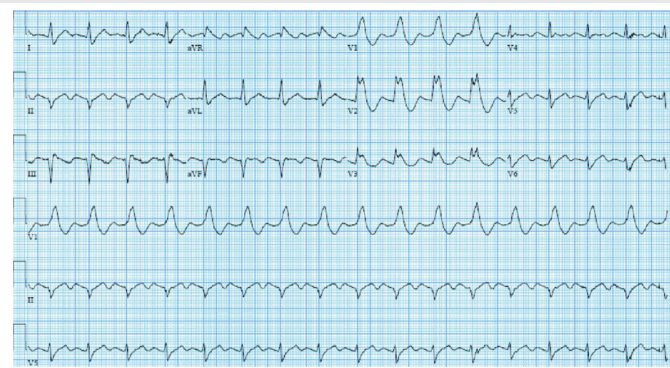


Figure 6: Admission electrocardiogram in patient presenting for nausea and dizziness after administration of loading dose of propafenone. ECG is notable for a regular, wide complex tachycardia with right bundle branch and left anterior fascicular block.

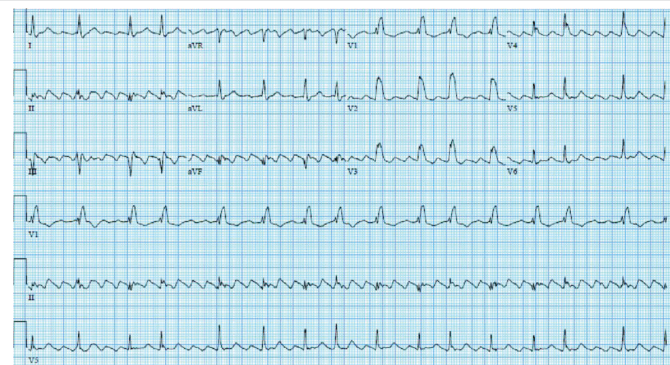


Figure 7: Electrocardiogram obtained 5 minutes after administration of sodium bicarbonate demonstrated dramatic narrowing of the QRS complex and emergence of atrial flutter with variable block.

Discussion

Antiarrhythmic agents are commonly used to help maintain sinus rhythm. We present two cases where knowledge of a drug's pharmacology and side effect profile allowed for prompt diagnosis and treatment. Class IC anti-arrhythmic agents, consisting primarily of flecainide and propafenone, interfere with cardiac myocyte sodium channels and are often referred to as "membrane stabilizing agents." They function by decreasing the excitogenicity of the plasma membrane. The efficacy of Class IC agents has been well documented in the medical literature leading to widespread use for both acute termination and chronic suppression of supraventricular arrhythmias in patients with structurally normal hearts [7–9].

Despite their proven efficacy, both agents are associated with infrequent but notable adverse events, particularly if their clearance is decreased (Table 1). Flecainide is hepatically metabolized, but has 30% renal clearance, and has been linked to heart failure exacerbations, acute rise in pacing thresholds, pro-arrhythmias, and conduction abnormalities [10]. Due to these associations, flecainide should not be initiated in any patient with known or suspected cardiomyopathy and withdrawn in patients who develop a cardiomyopathy during its use [11]. In patients with pre-existing pacemakers, thresholds should be interrogated after initiation of flecainide and appropriate adjustments made [12]. Perhaps the most worrisome adverse property of flecainide is its ability to induce ventricular tachyarrhythmias in the setting of QRS prolongation [13]. In fact, widening of the QRS by more than 50% with exercise predicts the risk of ventricular arrhythmias [14]. If a ventricular tachyarrhythmia is precipitated, flecainide should be discontinued indefinitely. In the first case, the patient developed acute renal failure in the setting of pneumonia. This likely contributed to the pro-arrhythmic effect with ventricular tachycardia due to flecainide toxicity.

Our second patient self-administered propafenone for acute conversion, which has been termed "pill in the pocket approach." The ability of these agents to acutely abort a paroxysm of AFib is also well documented in the literature. Boriani et al. conducted a multi-center, randomized controlled study comparing the efficacy of oral propafenone versus placebo for conversion to sinus rhythm. Eight hours after drug administration, 76% of patients treated with propafenone had successfully converted to sinus rhythm, compared to 37% of

Table 1:

	Flecainide	Propafenone
Usual Dose	50-100 mg bid	150-300 mg tid
Maximum Dose	300 mg/day	900 mg/day
Metabolism	Hepatic	Hepatic
Clearance	Renal	Hepatic
AVN agent suggested	Yes	Yes
Drug Interaction		
Digoxin	No	Yes
Warfarin	No	Yes
Amiodarone	Yes	Yes

patients in the placebo group [15]. Alboni et al., studied the efficacy and safety of this approach using either propafenone or flecainide. Limited to patients with either mild heart disease or no heart disease, the study found the “pill-in-the-pocket” approach to be effective in terminating 94% of arrhythmic episodes [16].

Our patient was noted to have wide QRS with bundle branch block, atrial flutter and faster ventricular rate. Class 1 Agents have a small risk of converting atrial fibrillation into atrial flutter in an estimated 5% of the cases due to slower atrial cycle length. This enables 1:1 conduction at the level of AV node, therefore these drugs are administered along with atrioventricular nodal inhibitors such as beta blockers, calcium channel blockers or digoxin. Conduction abnormalities generally consist of widening of the QRS to frank bundle branch development or to high degree AV block due to sodium channel blocking effect and slowing of conduction in His Purkinje system.

Propafenone is cleared primarily by hepatic metabolism via the cytochrome P450 2D6 complex and also through the 1A2 and 3A4 complexes. There are two genetically determined forms of metabolism, fast and slow. Metabolism of the drug yields a half-life of 7 hours in the “fast” metabolizers and as long as 17 hours in the slow metabolizers. However, in patients that are “normal” metabolizers of propafenone, the elimination half-life is approximately 5–8 hours [17]. Propafenone also has non-linear pharmacokinetics: increasing the dose from 300mg to 900mg results in a 10-fold increase in serum concentrations [18,19] (Table 1). Similar to flecainide, the greatest concern with propafenone is its ability to promote ventricular tachyarrhythmias in relation to its ability to prolong the QRS interval [15]. Even with normal therapeutic concentrations, propafenone can induce a 15–25% widening of the QRS [18]. While there are no specific guidelines, most authors suggest decreasing the dose or discontinuing the agent if the QRS prolongs by greater than 50% at rest or with exercise. Gastrointestinal and neurological symptoms, such as nausea, vomiting, lightheadedness and dizziness as noted in our second patient, are among the most frequently reported self-limiting side effects associated with propafenone use occurring in up to 10% of patients even in patients with therapeutic concentrations. All of these reported toxicities and adverse events are rare with both these agents and occur infrequently in patients with normal clearance of the drug. However, care must be taken to withdraw them in patients with worsening clearance and avoid excessive ingestion.

Awareness and recognition are perhaps the two most important aspects of managing toxicities of any pharmacologic agent. The case presentations and discussion in this review emphasize the importance of understanding the pharmacokinetic profiles and metabolism of Class IC anti-arrhythmic drugs (Table 1). Toxicity of these drugs is suspected when there is at least a 50% increase in the QRS duration, and/or 30% and 15% increases in the PR and QTc intervals, respectively [20,21]. When toxicity is suspected, the first goal of care is supportive treatment. Gastric decontamination can theoretically be attempted but may be of limited utility if the

ingestion is not acute. In addition to standard resuscitation measures, sodium bicarbonate is widely accepted as the first agent used to counter the effects of all Class IC agents. Sodium bicarbonate overcomes the potent sodium-channel blockade produced by class IC antiarrhythmics; sodium bicarbonate competitively displaces propafenone and flecainide from its binding site on cardiac myocyte sodium channels and the alkalization of serum pH inhibits further binding of these agents [22]. In its most concentrated form (ampules), sodium bicarbonate can be given in bolus form at the bedside 50 mEq at a time. With this strategy the displacement of Class IC agents from the sodium channel will only last momentarily as the elevated concentrations of the Class IC drug will once again overwhelm the sodium channel receptors. In patients who show transient clinical improvement with sodium bicarbonate boluses and have no clinical evidence of heart failure, continuous (3%) sodium bicarbonate or (3%) hypertonic saline infusions have been suggested. This will provide persistently elevated sodium concentrations to allow longer displacement of the drug from the sodium channel receptors. The infusions are continued until enough time has lapsed for the drug to be metabolized or cleared.

Both flecainide and propafenone are lipophilic and have large volumes of distribution; hence, there is theoretically a minimal role for hemodialysis in the setting of acute ingestion. This was confirmed in a few isolated case reports [23–25]. Where neither hemodialysis nor hemofiltration resulted in improved clearance of the agent. Owing to their lipophilic properties and large volume of distribution, the use of intravenous fat emulsion therapy has been successfully used in the cases of both flecainide and propafenone toxicity [26–29]. Intravenous fat emulsion therapy is hypothesized to function as a lipid sink, recruiting and then sequestering lipophilic medications from the receptor sites where the toxicity is mediated. Current recommendations for administration of a bolus consisting of 1.5 mL/kg of 20% intravenous fat emulsion over 2–3 minutes, followed by a continuous infusion of 0.25 mL/kg/min for one hour [30]. Finally, in patients with refractory toxicity the use of extracorporeal life support has been reported in isolated cases of flecainide toxicity, but is almost always used as last resort strategy [31,32].

Conclusion

Class IC agents (flecainide and propafenone) are effective anti-arrhythmic agents for the treatment of atrial and ventricular tachyarrhythmias in patients without structural heart disease. They are generally very well tolerated but their toxicities are noteworthy, and physicians need to be aware of the precipitating factors and management strategies.

References

1. Kannel WB, Wolf PA, Benjamin EJ, Levy D (1998) Prevalence, incidence, prognosis, and predisposing conditions for atrial fibrillation: population-based estimates. *Am J Cardiol* 82: 2N-9N. [Link: https://goo.gl/NjAg38](https://goo.gl/NjAg38)
2. Van Gelder IC, Groenveld HF, Crijns HJ, Tuininga YS, Tijssen JG, et al. (2010) Lenient versus strict rate control in patients with atrial fibrillation. *N Engl J Med* 362:1363-1373. [Link: https://goo.gl/wfYp5F](https://goo.gl/wfYp5F)

3. Wyse DG, Waldo AL, DiMarco JP, Domanski MJ, Rosenberg Y, et al. (2002) A comparison of rate control and rhythm control in patients with atrial fibrillation. *N Engl J Med* 347: 1825-1833. [Link: https://goo.gl/6X2BD1](https://goo.gl/6X2BD1)
4. January CT, Wann LS, Alpert JS, Calkins H, Cigarroa JE, et al. (2014) AHA/ACC/HRS guideline for the management of patients with atrial fibrillation: executive summary: a report of the American College of Cardiology/American Heart Association Task Force on practice guidelines and the Heart Rhythm Society. *Circulation* 130:2071-2104. [Link: https://goo.gl/oGiMg6](https://goo.gl/oGiMg6)
5. Piccini JP, Mi X, DeWald TA, Go AS, Hernandez AF, et al. (2012) Pharmacotherapy in Medicare beneficiaries with atrial fibrillation. *Heart Rhythm* 9:1403-1408. [Link: https://goo.gl/De41A1](https://goo.gl/De41A1)
6. Crijns HJ (2005) Rate versus rhythm control in patients with atrial fibrillation: what the trials really say. *Drugs* 65:1651-1667. [Link: https://goo.gl/7EHnPa](https://goo.gl/7EHnPa)
7. Reimold SC, Maisel WH, Antman EM (1998) Propafenone for the treatment of supraventricular tachycardia and atrial fibrillation: a meta-analysis. *Am J Cardiol* 82: 66N-71N. [Link: https://goo.gl/3AZ3Q4](https://goo.gl/3AZ3Q4)
8. Falk RH, Fogel RI (1994) Flecainide. *J Cardiovasc Electrophysiol* 5: 964-981.
9. Cobbe SM, Rae AP, Poloniecki JD, Chong E, Balnave K, et al. (1995) A randomized, placebo-controlled trial of propafenone in the prophylaxis of paroxysmal supraventricular tachycardia and paroxysmal atrial fibrillation UK Propafenone PSVT Study Group. *Circulation* 92: 2550-2557. [Link: https://goo.gl/MqsaRF](https://goo.gl/MqsaRF)
10. Andrikopoulos GK, Pastromas S, Tzeis S (2015) Flecainide: Current status and perspectives in arrhythmia management. *World J Cardiol* 7: 76-85. [Link: https://goo.gl/gbVUTg](https://goo.gl/gbVUTg)
11. Josephson MA, Ikeda N, Singh BN. (1984) Effects of flecainide on ventricular function: clinical and experimental correlations. *Am J Cardiol* 53: 95B-100B. [Link: https://goo.gl/aioVn4](https://goo.gl/aioVn4)
12. Hellestrand KJ, Nathan AW, Bexton RS, Camm AJ (1984) Electrophysiologic effects of flecainide acetate on sinus node function, anomalous atrioventricular connections, and pacemaker thresholds. *Am J Cardiol* 53: 30B-38B. [Link: https://goo.gl/6U5n38](https://goo.gl/6U5n38)
13. Morganroth J, Horowitz LN (1984) Flecainide: its proarrhythmic effect and expected changes on the surface electrocardiogram. *Am J Cardiol* 53: 89B-94B. [Link: https://goo.gl/ZyEdjd](https://goo.gl/ZyEdjd)
14. Fuster V, Rydén LE, Cannom DS, Crijns HJ, Curtis AB, et al. (2006) ACC/AHA/ESC 2006 Guidelines for the Management of Patients with Atrial Fibrillation: a report of the American College of Cardiology/American Heart Association Task Force on Practice Guidelines and the European Society of Cardiology Committee for Practice Guidelines (Writing Committee to Revise the 2001 Guidelines for the Management of Patients With Atrial Fibrillation): developed in collaboration with the European Heart Rhythm Association and the Heart Rhythm Society. *Circulation* 114: e257-354. [Link: https://goo.gl/DMfx3c](https://goo.gl/DMfx3c)
15. Boriani G, Biffi M, Capucci A, Botto GL, Broffoni T, et al. (1997) Oral propafenone to convert recent-onset atrial fibrillation in patients with and without underlying heart disease. A randomized, controlled trial. *Ann Intern Med* 126: 621-625. [Link: https://goo.gl/7pkaaN](https://goo.gl/7pkaaN)
16. Alboni P, Botto GL, Baldi N, Luzi M, Russo V, et al. (2004) Outpatient treatment of recent-onset atrial fibrillation with the "pill-in-the-pocket" approach. *N Engl J Med* 351: 2384-2391. [Link: https://goo.gl/L2yAac](https://goo.gl/L2yAac)
17. Miller JM, Zipes, DP (2012) Therapy for Cardiac Arrhythmias. In Braunwald's heart disease: a textbook of cardiovascular medicine, 9th edition. Edited by R Bonow D. Mann D. Zipes, & P. Libby, Saunders, Philadelphia USA 710-744.
18. Grant AO (1996) Propafenone: an effective agent for the management of supraventricular arrhythmias. *J Cardiovasc Electrophysiol* 7: 353-364. [Link: https://goo.gl/dfs5DH](https://goo.gl/dfs5DH)
19. Yeung A, Shanks D, Parwana H, Gin K (2010) Acute propafenone toxicity after two exposures at standard dosing. *Can J Cardiol* 26: 209-210. [Link: https://goo.gl/1xS1Wi](https://goo.gl/1xS1Wi)
20. Köppel C, Oberdisse U, Heinemeyer G (1990) Clinical course and outcome in class IC antiarrhythmic overdose. *J Toxicol Clin Toxicol* 28: 433-444. [Link: https://goo.gl/Mg2S1b](https://goo.gl/Mg2S1b)
21. Greig J, Groden BM (1995) Persistent electrocardiographic changes after flecainide overdose. *Br J Clin Pract* 49: 218-219. [Link: https://goo.gl/QMfK3n](https://goo.gl/QMfK3n)
22. Brubacher J (2004) Bicarbonate therapy for unstable propafenone-induced wide complex tachycardia. *CJEM* 6: 349-356. [Link: https://goo.gl/YHtJ38](https://goo.gl/YHtJ38)
23. Dirks E, Gieshoff B, Stahlmann R, Wehr M, Hager W (1990) Successful treatment of flecainide (Tambacor) poisoning—effect of hemodialysis/hemoperfusion?. *Z Kardiol* 79: 54-59. [Link: https://goo.gl/XYmsiu](https://goo.gl/XYmsiu)
24. Borgeat A, Biollaz J, Freymond B, Bayer-Berger M, Chioloro R (1988) Hemofiltration clearance of flecainide in a patient with acute renal failure. *Intensive Care Med* 14: 236-237. [Link: https://goo.gl/rm5TvH](https://goo.gl/rm5TvH)
25. Burgess ED, Duff HJ (1989) Hemodialysis removal of propafenone. *Pharmacotherapy* 9: 331-333. [Link: https://goo.gl/6XKSzM](https://goo.gl/6XKSzM)
26. Ellsworth H, Stellpflug SJ, Cole JB, Dolan JA, Harris CR (2013) A life-threatening flecainide overdose treated with intravenous fat emulsion. *Pacing Clin Electrophysiol* 36: e87-89. [Link: https://goo.gl/GjL3KG](https://goo.gl/GjL3KG)
27. Moussot PE, Marhar F, Minville V, Vallé B, Dehours E, et al. (2011) Use of intravenous lipid 20% emulsion for the treatment of a voluntary intoxication of flecainide with refractory shock. *Clin Toxicol (Phila)* 49: 514. [Link: https://goo.gl/rjuk58](https://goo.gl/rjuk58)
28. ten Tusscher BL, Beishuizen A, Girbes AR, Swart EL, van Leeuwen RW (2011) Intravenous fat emulsion therapy for intentional propafenone intoxication. *Clin Toxicol (Phila)* 49: 701. [Link: https://goo.gl/xsUaz7](https://goo.gl/xsUaz7)
29. Jacob J, Heard K (2011) Second case of the use of intravenous fat emulsion therapy for propafenone toxicity. *Clin Toxicol (Phila)* 49: 946-947. [Link: https://goo.gl/Tcd9S9](https://goo.gl/Tcd9S9)
30. American College of Medical Toxicology (2011) ACMT position statement: interim guidance for the use of lipid resuscitation therapy. *J Med Toxicol* 7: 81-82. [Link: https://goo.gl/PpXxFo](https://goo.gl/PpXxFo)
31. Vivien B, Deye N, Mégarbane B, Marx JS, Leprince P, et al. (2010) Extracorporeal life support in a case of fatal flecainide and betaxolol poisoning allowing successful cardiac allograft. *Ann Emerg Med* 56: 409-412. [Link: https://goo.gl/xXJQ4q](https://goo.gl/xXJQ4q)
32. Auzinger GM, Scheinkestel CD (2001) Successful extracorporeal life support in a case of severe flecainide intoxication. *Crit Care Med* 29: 887-890. [Link: https://goo.gl/rJ4nga](https://goo.gl/rJ4nga)