



Medical Group

# Journal of Cardiovascular Medicine and Cardiology

DOI <http://doi.org/10.17352/2455-2976.000060>

ISSN: 2455-2976

CC By

**Vincenzo Cianci\*, Natalia Scialacomo, Debamalya Ray and Prof. Federico Benetti**

Cardiac Surgery Benetti Foundation, Rosario Argentina

**Received:** 06 February, 2018

**Accepted:** 12 March, 2018

**Published:** 13 March, 2018

**\*Corresponding author:** Vincenzo Cianci, Cardiac Surgery Benetti Foundation, Rosario Argentina, E-mail: cianenz@hotmail.com

**Keywords:** Hybrid revascularization; MINI OPCAB mammary to Lad and stenting; Minimally invasive coronary surgery; Hybrid Revascularization another option

<https://www.peertechz.com>

## Surgical Technique

# MINI-OPCABG an option in Hybrid coronary revascularization

MIDCAB and MINI OPCAB. Ten patients were treated with hybrid revascularization, using MINIOPCABG technique, the average age was  $71 \pm 4.8$ , two patients had left main and right coronary lesion, four patient three vessels disease and four patients had two vessel disease. The average Euroscore II was 7.60% (range 0.33-19.34), the average SYNTAX score was 35.2 (range33-43). Every patient received Lima to Lad with MINIOPCABG, Four patients received circumflex and right coronary artery stenting, another three patients' only right coronary stenting, three patients' only circumflex stenting. The whole procedure which included Surgery (MINI-OPCABG) and Percutaneous Coronary Intervention (PCI) with Drug Elluting Stent (DES with Evorlimus) as a single stage procedure.

Pre-operative and operative characteristics are illustrated in table 1.

## Introduction

Hybrid coronary revascularization (HCR) combines minimally invasive left internal mammary artery to left anterior descending bypass with percutaneous coronary intervention of non-left anterior descending vessels. And it is feasible and appeared to be safe, with faster recovery and similar outcomes when compared with conventional CABG [1-4]. Also Hybrid coronary revascularization is a viable option to perform a minimally invasive, functionally complete revascularization in high-risk patients instead of conventional revascularization [5], robotic-assisted LITA harvesting and a small left anterior thoracotomy survival, freedom from angina and freedom from revascularization also appear favorable at the 5-year clinical follow-up [6]. Closed chest hybrid revascularization is another although more complex option [7].

The variability in hybrid coronary revascularization techniques makes it difficult to draw firm conclusions from the currently evidences in terms of cost /effective strategy and a technique easy to reproduce, The hybrid strategy using MINI-OPCAB appears to be a promising and cost-effective alternative for CABG in the treatment of multi vessel coronary artery disease .

We describe our initial experience in hybrid coronary revascularization using MINI-OPCAB technique and we point out about methodology used [8,9].

## Materials and Methods

From 1990 to 2017 58 patients received Hybrid coronary treatment in ours Institutions with different surgical off pump approaches, Sternotomy, Limited no opening Sternotomy,

**Table 1:** Preoperative and Operative Characteristics of Patients.

No. of Patients	10
Age,years	71.2±4.8
Female gender	2 (20%)
BMI, Kg/m2	27.2±4.4
Euroscope II	7.6(0.3-19.3)
Syntax Score	35.2(33-43)
LMS Disease	2 (20%)
LMS and RCA Disease	2 (20%)
Two vessel disease	4 (40%)
Number of Stents	
1	6 (60%)
2	4 (40%)
30- days mortality	0
MACCE	0
Blood transfusion	2 (20%)
Conversion to Sternotomy	0
Incubation time, hours	1.5±3.2
Total length of stay, days	3.2±1.2

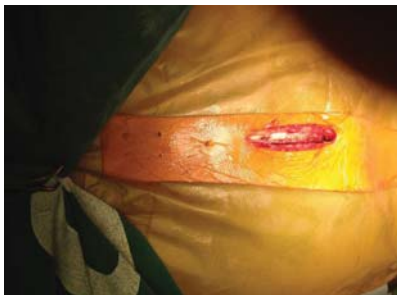Definitions: BMI: Body Mass Index, LMS: Left main stem, RCA: Right coronary artery, MACCE: Major adverse cardiovascular events.

## Surgical Technique

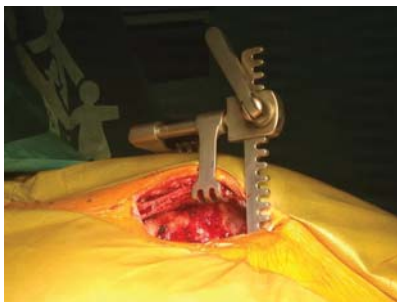
A skin incision is made from the xiphoid up to the level between the fourth and third intercostal space (Figure 1). The hemi-sternum is opened and the left table is lifted to dissect the left mammary artery (LIMA) (Figure 2) The LIMA was dissected up to the third intercostal space and skeletonized. The angle of the superior part where the LIMA is attached to the sternum needs to be below 20 degrees to avoid any potential kinking (Figure 3) The pericardium is open from the left border of the pulmonary artery down to the apex of the heart In most of the cases you see directly the LAD, in this moment you measure the distance of the mammary to avoid any kinking (Figure 4), two stitches about 2 cm deep in the left border of the pericardium are placed with a distance of 5 to 7 cm for better exposure of the Left Anterior Descending (LAD) artery (Figure 5). The retractor is change on the anastomosis is performed with a mechanical stabilizer with the opening part towards the head of the patient to avoid any problem of damaging the graft. The stenting were done in different time frames our actual tendency like in the last 5 patients we performed the complete revascularization in single stage after LIMA to LAD, under general anaesthesia we infused from the nasogastric tube, clopidogrel (300mg) and didn't revert the Heparin (1,5mg /KG), and with chest open non LAD vessel was stented after angiographic control of the mammary anastomosis (Figure 5).

## Results

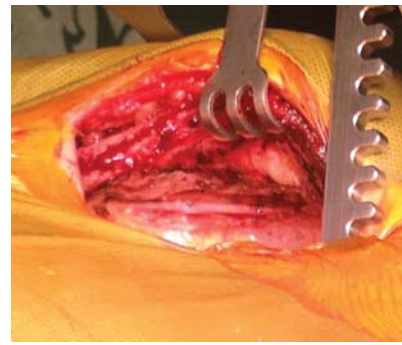
No thirty day mortality was reported in our series. All patients completed hybrid procedure and there wasn't any conversion to full sternotomy. Mean intubation time was  $1.5 \pm 3.2$  hrs and length of hospital stay was  $3.2 \pm 1.2$  days, two patients received packed RBC (red blood cells) transfusion,



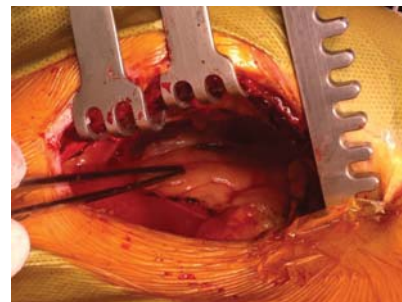
**Figure 1:** A skin incision is made from the xiphoid up to the level between the fourth and third intercostal space.



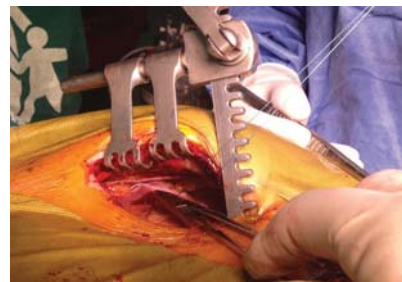
**Figure 2:** The hemi-sternum is opened and the left table is lifted to dissect the left mammary artery (LIMA).



**Figure 3:** The LIMA was dissected up to the third intercostal space and skeletonized. The angle of the superior part where the LIMA is attached to the sternum needs to be below 20 degrees to avoid any potential kinking.



**Figure 4:** The pericardium is open from the left border of the pulmonary artery down to the apex of the heart. In most of the cases you see directly the LAD, in this moment you measure the distance of the mammary to avoid any kinking.



**Figure 5:** Two stitches about 2 cm deep in the left border of the pericardium are placed with a distance of 5 to 7 cm for better exposure of the Left Anterior Descending (LAD) artery.

hospital MACCE was 0%. During PCI procedure angiographic evaluation LIMA grafting was routinely performed and LIMA patency rate was 100% at one year follow up freedom from MACCE was 100%.

## Conclusion

In 1997 we performed for the first time in the world an ambulatory coronary surgery using the xiphoid approach. We modified this technique opening a small distal part of sternum and we call this technique MINI-OPCABG. The potential advantage of the MINI OPCABG versus MIDCABG operation is:

- 1) MINI OPCABG operation is easy to convert to full sternotomy.
- 2) Post operatively patients had less painful based on a patient scoring system of rating between 0-10.

- 3) A potential quicker recovery time.
- 4) Reduction of hospital cost for the combined procedure by 27% and a reduction in in-patient stay costs by 22%.

The introduction of DES with lower rates of restenosis and better clinical outcomes may make hybrid coronary revascularization a more sustainable and feasible option than previously reported. Nevertheless, this hybrid approach has not been widely adopted because practical and logistical concerns have been expressed. These concerns implicate the need for close cooperation between surgeon and interventional cardiologist, logistical issues regarding sequencing and timing of the procedures and the use of aggressive antiplatelet therapy for DES can be minimised. We believe that with MINI-OPCABG can solve these issues because this surgical technique reduces the surgical trauma without opening pleural space with less discomfort for the patient, moreover the partial dissection of LIMA reduces the risk of post-operative bleeding

The HCR procedure was associated with short hospital stays (including ICU stay and intubation time), low MACCE and 30-day mortality rate, low PRBC transfusion requirements. This study has limitations because it was based on the retrospective design, moreover patients for one stop hybrid coronary revascularization were also carefully selected and our good results should be interpreted with caution. However there is a small sample size and long term follow-up and randomized multicenter trial comparing one stop hybrid revascularization with MINI-OPCABG with conventional CABG will be needed.

These favorable preliminary findings warrant further investigation.

- Cardiovascular Medicine. Org/105772/50852. Edited by Wilbert S. Aronow. March 2013.
- Statistics Calculations (SPSS version 15)

- Statistics. Data were analyzed with the Statistical Package for Social Sciences (SPSS, Version 15.0)

## References

1. Benetti FJ (2012) In Tech chirurgie thoracique Cardio-Vasculaire 16: 69-71. [Link: https://goo.gl/TNfAZ4](https://goo.gl/TNfAZ4)
2. Benetti FJ (2008) Xiphoid approach long term results. Edited by Heart Surg Forum. 18th World Congress - World Society of Cardio-Thoracic Surgeons. Kos Island 11.
3. Reicher B, Poston RS, Mehra MR, oshi A, Odonkor P, et al. (2008) "Simultaneous "hybrid" percutaneous coronary intervention and minimally invasive surgical bypass grafting: feasibility, safety, and clinical outcomes," Am Heart J 155: 661-667. [Link: https://goo.gl/ch6Dyg](https://goo.gl/ch6Dyg)
4. Holzhey DM, Jacobs S, Mochalski M, Merk D, Walther T, et al. (2008) "Minimally invasive hybrid coronary artery revascularization," Annals of Thoracic Surgery, vol. 86, no. 6, pp. 1856-1860. [Link: https://goo.gl/W89vro](https://goo.gl/W89vro)
5. Angelini GD, Wilde P, Salerno TA, Bosco G, Calafiore AM (1996) Integrated left small thoracotomy and angioplasty for multivessel coronary artery revascularization. Lancet 347: 757-758. [Link: https://goo.gl/2a1Rn8](https://goo.gl/2a1Rn8)
6. Harskamp RE, Bagai A, Halkos ME, Rao SV, Bachinsky WB, et al. (2014) Clinical outcomes after hybrid coronary revascularization versus coronary artery bypass surgery: a meta-analysis of 1,190 patients. Am Heart J 167: 585-592. [Link: https://goo.gl/CEWVwb](https://goo.gl/CEWVwb)
7. Hu S, Li Q, Gao P, Xiong H, Zheng Z, et al. (2011) Simultaneous hybrid revascularization versus off-pump coronary artery bypass for multivessel coronary artery disease. Ann Thorac Surg 91: 432-438. [Link: https://goo.gl/jJgYoe](https://goo.gl/jJgYoe)
8. Holzhey DM, Cornely JP, Rastan AJ, Davierwala P, Mohr FW (2012) Review of a 13-year single-center experience with minimally invasive direct coronary artery bypass as the primary surgical treatment of coronary artery disease. Heart Surg Forum 15: E61-8. [Link: https://goo.gl/VqX5s1](https://goo.gl/VqX5s1)
9. Shannon J, Colombo A, Alfieri O (2012) Do hybrid procedures have proven clinical utility and are they the wave of the future: hybrid procedures have proven clinical utility and are the wave of the future. Circulation 125: 2492-503. [Link: https://goo.gl/5QwvCF](https://goo.gl/5QwvCF)