



Research Article

Descending thoracic aorta to bifemoral bypass grafting in Aortobiiliac occlusive disease

Suraj Wasudeo Nagre*

Associate Professor, Department of CVTS, Grant Medical College, Mumbai, India

Received: 31 August, 2020

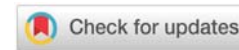
Accepted: 11 September, 2020

Published: 12 September, 2020

*Corresponding author: Dr. Suraj Wasudeo Nagre, Associate Professor, Department of CVTS, Grant Medical College, 31, Trimurti Building, J J Hospital Compound, Byculla, Pin -400008, Mumbai, India, Tel: 09967795303, E-mail: surajnagre@yahoo.com

Keywords: Aorta; Atherosclerosis; Thoraco-bifemoral bypass

<https://www.peertechz.com>



Abstract

Introduction: The aim of this prospective study is to describe the clinical symptoms, investigation findings and surgical treatment of aortoiliac occlusive disease where abdominal approach not feasible or not possible for aortobifemoral bypass grafting.

Method: From May 2013 to May 2019, ten patients were treated with descending thoracic aorto-bifemoral bypass for aortoiliac occlusive disease at Grant Medical College and JJ group of Hospitals, Mumbai (Maharashtra). Total 20 limbs were re-vascularized. Demographic data, co-morbid factors, per operative findings were noted. Indication for surgery is juxtarenal occlusion of the abdominal aorta, in most of the cases. In postoperative period, all patients were evaluated for appearance of distal pulsations, primary patency, warmth of foot, symptom relief, wound infection, healing of the ulcer, and complications. CT angiography was done in follow-up. Maximal followup of two years and minimum followup of one month was done after surgery.

Results: No mortality. Mean duration of surgery was 2.5-5 h and mean blood loss was 250 - 400 mL. Major morbidity includes one graft occlusion. None of the patients developed proximal propagation of aortic thrombus. Ulcers showed healing. All patients had a good quality of life postoperatively. Postoperative angiography showed good re-vascularization.

Conclusion: Majority of our patients are old age having juxtarenal aortic occlusion so we decided to use DTA as inflow for primary revascularization to avoid entering abdomen and renal injury. Some authors have recommended supraceliac aorta bypass surgery within the retroperitoneal space for juxtarenal aortic occlusive disease but is technically difficult and associated with morbidity. The major limitation to thoracic aorta bifemoral grafting technique is the morbidity rate associated with thoracotomy in a relatively high-risk vascular surgery population. Also, tunnelling in conventional DTA-to-femoral artery bypass is usually a "blind" procedure. For the cardiothoracic surgeon with experience, the use of descending thoracic aorta could be a very good alternative for infrarenal aortic occlusion or extra-anatomic aortoiliac bypass without any morbidity and mortality with good improvement in quality of life.

Introduction

The standard method of aortoiliac re-vascularization for occlusive disease is through a transabdominal approach. When this option is not feasible, descending thoracic aorto-bifemoral bypass grafting is a good alternative. The purpose of this prospective study was to evaluate the effectiveness and results of the descending thoracic aorta as an inflow source for aortoiliac re-vascularization in cases where transabdominal approach was considered to be hazardous. Descending thoracic aorta to femoral artery bypass has been used as a remedial operation after aortic or axillofemoral graft failure or graft infection and other intra-abdominal pathologies not amenable to standard aortofemoral revascularization. It can avoid abdomen approach and has been known as a durable procedure with excellent

long-term patency. The aim of study is to describe the clinical symptoms, investigation findings and surgical treatment of aortoiliac occlusive disease where abdominal approach not feasible or not possible for aortobifemoral bypass grafting.

Material and method

From May 2013 to May 2019, ten patients were treated with descending thoracic aorto-bifemoral bypass for aortoiliac occlusive disease at Grant Medical College and J J group of Hospitals, Mumbai (Maharashtra). Total 20 limbs were re-vascularized. Demographic data, co-morbid factors, per operative findings were noted. Indication for surgery is juxtarenal occlusion of the abdominal aorta, in most of the cases.

All patients had disabling intermittent claudication or rest pain. Six patients were in Rutherford’s Class IV with rest pain, two patients were in Class V with ischemic ulcers over toes and two patients were in Class III with severe claudication. Computed Tomography (CT) angiography showed juxtarenal aortic occlusion (Figure 1A). In addition two patients had left superficial femoral artery occlusion (Figure 1B) and one patient has right superficial femoral artery occlusion. Abdominal aorto-bifemoral was considered to be hazardous as there was no suitable site for aortic cross clamping as well as grafting. After discussing various surgical alternatives, we decided to perform descending thoracic aorta to both femoral artery bypass surgery. We used Gortex vascular graft for bypass surgery. Patients have various comorbidities that are shown in Table 1.

Surgical technique

Patients were given general anesthesia with hemodynamic monitoring. With double-lumen endo-tracheal intubation to allow deflation of the left lung, the patient was positioned

with the right semi-lateral position with the left hemi thorax elevated 30-45° and the pelvis as flat as possible to allow access to both groins. The chest, abdomen, and both groins were prepared and draped. Left posterolateral thoracotomy was performed through the eighth intercostal space, then, the distal descending thoracic aorta just above diaphragm and both femoral arteries were exposed simultaneously. Leaving the inguinal ligament intact, the oblique and transverse muscles of left side were split and the left retroperitoneal space was entered. Using blunt finger dissection, retroperitoneal tunneling was performed between the left hemithorax and the left suprainguinal preperitoneal space and cross over tunnel between both groin incisions was created similarly. After partial clamping on thoracic descending aorta with systemic heparinization, proximal anastomosis of a 14 mm × 7 mm Gortex bifurcated graft was performed end-to-side at the lower descending thoracic aorta (Figure 2). The graft limbs were drawn through a tunnel between rectus abdominus muscle and peritoneum to a short midline incision at level of umbilicus, from which each limb of the graft was drawn through a subcutaneous tunnel to each side of the groin and anastomosis to each common femoral artery. A chest tube (28Fr) was placed in the left pleural space and all incisions were closed. In postoperative period, all patients were evaluated for appearance of distal pulsations, primary patency, warmth of foot, symptom relief, wound infection, healing of the ulcer, and complications. CT angiography was done in follow-up. In Figure 3 CT angiography is showing normal flow pattern in graft.

Results

Ten patients with a range of 50-65 years of age, with a mean age of 58.6 years were treated in Grant Government Medical College, Mumbai, Maharashtra during study period. All patients were male. In literature female has less than 1% incidence of aortoiliac occlusive disease [1]. Pulmonary function tests showed mild chronic obstructive pulmonary disease in four patients. Other co-morbidities were coronary artery disease in one patient, hypertension in four patients, renal impairment in three patients, and diabetes in three patients (Table 1).

Indication for surgery is juxtarenal occlusion of the abdominal aorta, in most of the cases. No mortality. Mean duration of surgery was 2.5-5 h and mean blood loss was 250 - 400 mL (Table 2). Major morbidity includes one graft occlusion

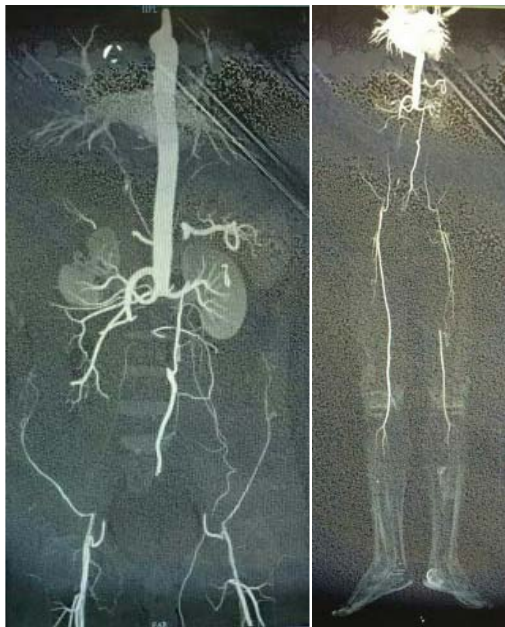


Figure 1: A] CT angiogram showing juxtarenal aortic occlusion B] CT angiogram showing juxtarenal aortic occlusion along with left superficial femoral artery occlusion.

Table 1: Clinical Data of patients with aortoiliac occlusion.

Case Number	Age	Sex	Indication	Comorbidities				
				DM	HT	Renal	Lung	CAD
1	58	Male	Juxtarenal aortoiliac occlusion	Yes	Yes	Mild Elevation	No	No
2	54	Male	Juxtarenal aortoiliac occlusion with left side superficial femoral artery occlusion	Yes	Yes	Mild Elevation	COPD	No
3	56	Male	Juxtarenal aortoiliac occlusion	No	Yes	No	No	No
4	62	Male	Juxtarenal aortoiliac occlusion	No	No	No	COPD	No
5	55	Male	Juxtarenal aortoiliac occlusion	No	No	No	No	No
6	57	Male	Juxtarenal aortoiliac occlusion with left side superficial femoral artery occlusion	Yes	Yes	Mild Elevation	No	Yes
7	61	Male	Juxtarenal aortoiliac occlusion	No	No	No	COPD	No
8	64	Male	Juxtarenal aortoiliac occlusion	No	No	No	No	No
9	58	Male	Juxtarenal aortoiliac occlusion with right side superficial femoral artery occlusion	No	Yes	No	No	No
10	59	Male	Juxtarenal aortoiliac occlusion	No	No		COPD	No
								278

which was treated successfully with embolectomy. None of the patients developed proximal propagation of aortic thrombus. Ulcers showed healing. All patients had a good quality of life postoperatively. Postoperative angiography showed good revascularization.

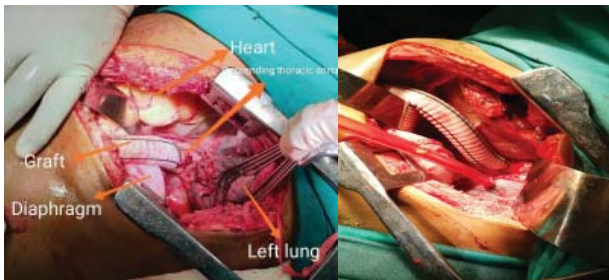


Figure 2: Proximal anastomosis of Gortex graft on descending thoracic aorta through left thoracotomy.

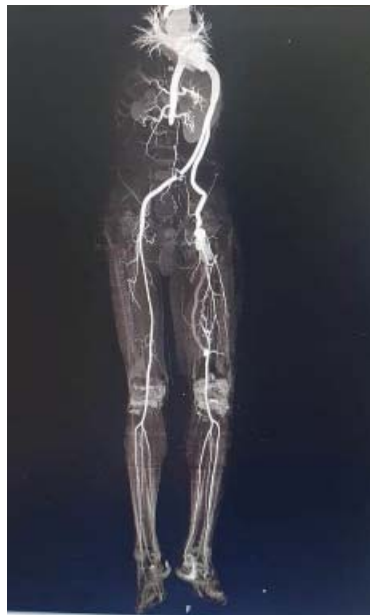

Figure 3: Postop CT Angiogram showing descending thoracic aorta to bifemoral bypass graft.

Table 2: Operative Data of patients with juxtarenal aortoiliac occlusion.

Case Number	Duration of Surgery (Hours)	Blood Loss (ml)	Complication	Outcome
1	4.5	400	Superficial Wound Infection	Managed Conservatively
2	5	400	Graft Occlusion	Embolectomy done, Good flow postoperatively
3	4.3	380	None	Uneventful
4	4.1	400	None	Uneventful
5	4	300	Superficial Wound Infection	Managed Conservatively
6	3.5	340	Graft Occlusion	Embolectomy done, Good flow postoperatively
7	3.4	320	None	Uneventful
8	3.2	300	None	Uneventful
9	3	250	None	Uneventful
10	2.5	250	None	Uneventful

Discussion

Aorto-femoral bypass grafting is the standard surgical treatment for aortoiliac occlusive disease, partly because of a 5 years patency rate that exceeds 80% in many reports [1]. When abdominal aortic surgery is contraindicated because of severe disease at the inflow site, axillo-femoral bypass or thoraco-bifemoral bypass are alternative procedures [2]. Some authors have recommended supraceliac aorta bypass surgery within the retroperitoneal space for juxtarenal aortic occlusive disease but is technically difficult and associated with morbidity. Also while clamping the supraceliac aorta surgeon may damage renal arteries and hamper the blood supply to kidneys. So better to avoid this technique [2].

However, the results of axillo-femoral bypass are generally less than ideal in terms of patency and quality of life [3]. Thoraco-femoral bypass has major advantages over axillo-femoral bypass because it provides better inflow, requires a shorter graft length, offers better protection of the graft from infection and mechanical trauma, and carries a superior patency rate [4]. Thoraco-femoral bypass was first described by Blaisdell, et al. as an alternative to standard aorto-femoral bypass [3]. Criado, et al. [4] described 16 cases that in addition to those reported in the English language literature, gave a combined surgical mortality rate of 6.4% and the primary graft patency was 98% at 1-year, 88% at 2 years, and 70.4% at 5 years [5].

The risk of subsequent renal artery thrombosis is a concern with the use of thoraco-femoral bypass in patients with juxtarenal aortic occlusion [6]. Using radioisotope renography pre-operatively, Cevese and Gallucci confirmed normal renal perfusion up to 5 years after thoraco-femoral bypass in 6 patients with complete juxtarenal aortic occlusion [7,8]. In our patients, renal function tests were normal postoperatively in all cases.

In our series, one patient having coronary artery disease were advised coronary artery bypass grafting followed by thoraco-femoral bypass. But on patient's choice, thoraco-femoral bypass was done first.

While most of the patients having mild pulmonary function test impairment, diabetes or hypertension behave normally in the postoperative period and discharged uneventfully. In other series [9-11], the graft was tunneled through posterior aspect of diaphragm to the left short transverse incision from this to both femoral arteries, but in our study we tunneled the graft anteriorly through anterior aspect of the diaphragm to the short midline incision then to both femoral arteries. All patients have good distal pulses. Operative mortality rate was 0-12% in different series [12,13] but in our series of 10 patients, no operative mortality was there and late mortality was 25-36% in other series [14,15] due to myocardial infarction, renal failure, stroke, respiratory insufficiency or septicemia. In our series no mortality.

Graft failure or occlusion occurred in 4-30% cases on 3-5 years in another series. In our series one graft limb occluded,



which was managed by embolectomy, had good distal flow and patient made a good recovery. Our series demonstrated superior inflow, excellent quality of life, and more reliable patency with thoraco-bifemoral bypass. This approach is recommended in selected patients when conventional approaches to the abdominal aorta are considered hazardous.

Conclusion

Majority of our patients are old age having juxtarenal aortic occlusion so we decided to use descending thoracic aorta as inflow for primary revascularization to avoid entering abdomen and renal injury. The major limitation to thoracic aorta bifemoral grafting technique is the morbidity rate associated with thoracotomy in a relatively high-risk vascular surgery population. Also, tunnelling in conventional DTA-to-femoral artery bypass is usually a "blind" procedure. For the cardiothoracic surgeon with experience, the use of descending thoracic aorta could be a very good alternative for infrarenal aortic occlusion or extra-anatomic aortoiliac bypass without any morbidity and mortality with good improvement in quality of life.

Ethical approval

All procedures performed in studies involving human participants were in accordance with the ethical standards of the institutional and/or national research committee and with the 1964 Helsinki declaration and its later amendments or comparable ethical standards.

References

1. Kalman PG, Johnston KW, Walker PM (1991) Descending thoracic aortofemoral bypass as an alternative for aortoiliac revascularization. *J Cardiovasc Surg (Torino)* 32: 443-446. [Link: https://bit.ly/3m4EPvU](https://bit.ly/3m4EPvU)
2. Passman MA, Farber MA, Criado E, Marston WA, Burnham SJ, et al. (1999) Descending thoracic aorta to iliofemoral artery bypass grafting: a role for primary revascularization for aortoiliac occlusive disease? *J Vasc Surg* 29: 249-258. [Link: https://bit.ly/2FrqSqW](https://bit.ly/2FrqSqW)
3. Frazier OH, Oalman MC, Strong JP, Cooley DA (1987) Clinical applications of the supraceliac aorta: anatomical and pathologic observations. *J Thorac Cardiovasc Surg* 93: 631-633. [Link: https://bit.ly/3heuv0M](https://bit.ly/3heuv0M)
4. Kolvenbach R (2000) Regarding "Descending thoracic aorta to iliofemoral artery bypass grafting: a role for primary revascularization for aortoiliac occlusive disease?". *J Vasc Surg* 31: 410. [Link: https://bit.ly/2DNP72c](https://bit.ly/2DNP72c)
5. Criado E (1997) Descending thoracic aorta to femoral artery bypass: surgical technique. *Ann Vasc Surg* 11: 206-215. [Link: https://bit.ly/33dyohw](https://bit.ly/33dyohw)
6. Oh JH, Choo SJ, Kim EK, Lee CK, Park KS (1992) Supraceliac aorta bypass surgery for juxtarenal aortic occlusive disease: 2 cases. *Korean J Thorac Cardiovasc Surg* 25: 105-111. [Link: https://bit.ly/2ZrSfsq](https://bit.ly/2ZrSfsq)
7. Fukui S, Paraskevas N, Soury P, Gigou F (2010) Totally videoendoscopic descending thoracic aorta-to-femoral artery bypass. *J Vasc Surg* 51: 1560-1563. [Link: https://bit.ly/2DSHCXY](https://bit.ly/2DSHCXY)
8. Criado E, Johnson G, Burnham SJ, Buehrer J, Keagy BA (1992) Descending

thoracic aorta-to-iliofemoral artery bypass as an alternative to aortoiliac reconstruction. *J Vasc Surg* 15: 550-557. [Link: https://bit.ly/3iloqkD](https://bit.ly/3iloqkD)

9. Bowes DE, Youkey JR, Pharr WP, Goldstein AM, Benoit CH (1990) Long term follow-up of descending thoracic aorto-iliac/femoral bypass. *J Cardiovasc Surg (Torino)* 31: 430-437. [Link: https://bit.ly/3hshoJH](https://bit.ly/3hshoJH)
10. Cevese PG, Gallucci V (1975) Thoracic aorta-to-femoral artery by-pass. For the treatment of complete obstruction of the abdominal aorta at the level of the renal arteries. *J Cardiovasc Surg (Torino)* 16: 432-438. [Link: https://bit.ly/3hkq6JF](https://bit.ly/3hkq6JF)
11. McCarthy WJ, Mesh CL, McMillan WD, Flinn WR, Pearce WH, et al. (1993) Descending thoracic aorta-to-femoral artery bypass: Ten years' experience with a durable procedure. *J Vasc Surg* 17: 336-347. [Link: https://bit.ly/2Fv26pS](https://bit.ly/2Fv26pS)
12. Ihaya A, Chiba Y, Kimura T, Morioka K, Uesaka T (2001) Descending thoracic aortobifemoral bypass for aortoiliac occlusive disease. *Asian Cardiovasc Thorac Ann* 9: 97-100. [Link: https://bit.ly/2ZrIScd](https://bit.ly/2ZrIScd)
13. Blaisdell FW, McMattei GA, Gauder PJ (1961) Extraperitoneal thoracic aorta bifurcation prosthesis: Case reports. *Am J Surg* 102: 583-585. [Link: https://bit.ly/3ilw0vk](https://bit.ly/3ilw0vk)
14. Mii S, Mori A, Sakata H, Kawazoe N (1998) Fifteen-year experience in axillofemoral bypass with externally supported knitted Dacron prosthesis in a Japanese hospital. *J Am Coll Surg* 186: 581-588. [Link: https://bit.ly/3iRo4E](https://bit.ly/3iRo4E)
15. McMillan WD, McCarthy WJ (1999) Minimally invasive thoracoscopic thoraco-femoral bypass: A case report. *Cardiovasc Surg* 7: 251-254. [Link: https://bit.ly/2FjbCwL](https://bit.ly/2FjbCwL)

Discover a bigger Impact and Visibility of your article publication with Peertechz Publications

Highlights

- ❖ Signatory publisher of ORCID
- ❖ Signatory Publisher of DORA (San Francisco Declaration on Research Assessment)
- ❖ Articles archived in worlds' renowned service providers such as Portico, CNKI, AGRIS, TDNet, Base (Bielefeld University Library), CrossRef, Scilit, J-Gate etc.
- ❖ Journals indexed in ICMJE, SHERPA/ROMEO, Google Scholar etc.
- ❖ OAI-PMH (Open Archives Initiative Protocol for Metadata Harvesting)
- ❖ Dedicated Editorial Board for every journal
- ❖ Accurate and rapid peer-review process
- ❖ Increased citations of published articles through promotions
- ❖ Reduced timeline for article publication

Submit your articles and experience a new surge in publication services (<https://www.peertechz.com/submission>).

Peertechz journals wishes everlasting success in your every endeavours.

Copyright: © 2020 Nagre SW. This is an open-access article distributed under the terms of the Creative Commons Attribution License, which permits unrestricted use, distribution, and reproduction in any medium, provided the original author and source are credited.